



**HARKRIDER  
ENDODONTICS**



**ADAM K. HARKRIDER, DDS, MS**  
DIPLOMATE, AMERICAN BOARD OF ENDODONTICS

\_\_\_\_\_  
INTRODUCING

\_\_\_\_\_  
REFERRED BY:

PATIENT IS REFERRED FOR THE FOLLOWING:

ROOT CANAL THERAPY

RETREATMENT

DIAGNOSIS

ENDODONTIC SURGERY

1 2 3 4 5 6 7 8

9 10 11 12 13 14 15 16

32 31 30 29 28 27 26 25

24 23 22 21 20 19 18 17

PULP WAS EXPOSED

ASYMPTOMATIC

TOOTH HAS FRACTURE

LEAVE POST SPACE

PERIAPICAL RADIOLUCENCY

PREPROSTHETIC ENDODONTICS  
REQUIRED

NITROUS

SBE PROPHYLAXIS REQUIRED

RCT BEGUN

COMMENTS: \_\_\_\_\_

\_\_\_\_\_

\_\_\_\_\_

WHEN TREATMENT IS COMPLETE:

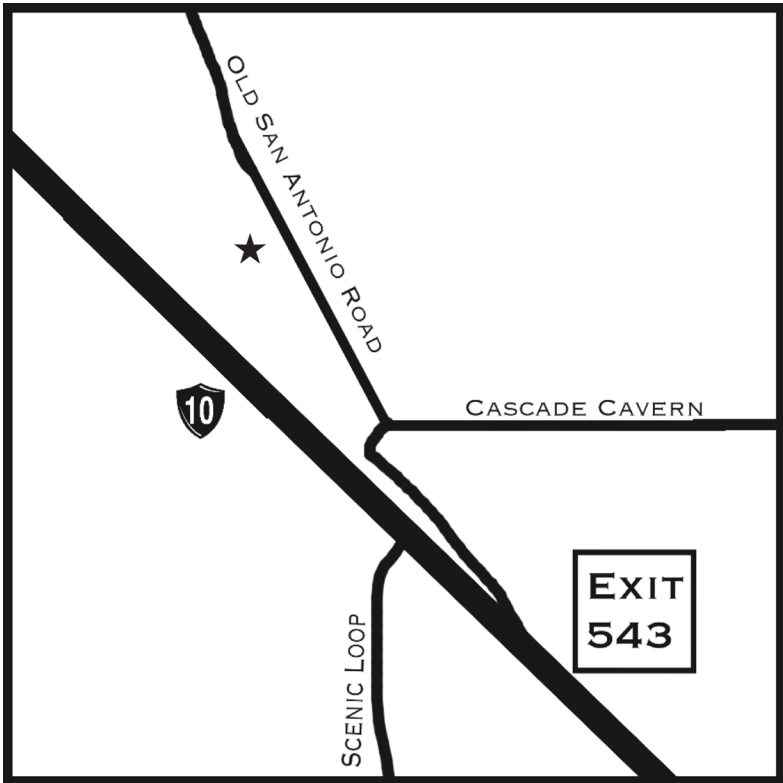
RESTORE ACCESS OPENING AS NEEDED

PREPARE POST SPACE

PLACE TEMPORARY RESTORATION

PLACE POST/BUILDUP AS NEEDED

SIGNED DR. \_\_\_\_\_



138 OLD SAN ANTONIO ROAD  
SUITE 501

BOERNE, TEXAS 78006

PHONE: (830) 431-9205

FAX: (830) 331-2134

OFFICE@HARKRIDERENDO.COM